

mmpc[®]
Michigan Medical, P.C.

"Putting Patients First"

Case Study

Erik C. Hedlund, DO
mmpc Orthopaedic Surgeon
4069 Lake Drive
Grand Rapids
616.464.2860



www.mmpc.com

Overview

Case Study

In recent years there has been development of arthroscopic instrumentation that has enabled orthopaedic surgeons to do some shoulder repairs through smaller incisions. Rotator cuff repairs, labrum repair, and distal clavicle excision are a few examples of techniques that can be done through an all arthroscopic approach.

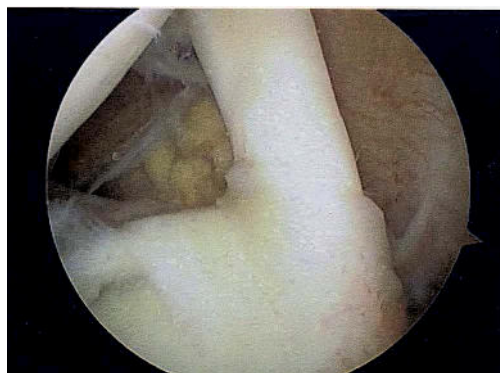
Minimally invasive techniques have the advantage of smaller incisions, less postoperative pain, and avoiding deltoid muscle rupture or dysfunction associated with more extensive approaches. It is important to realize that tissue repairs still heal at the same rate (tendon to bone healing) and will need to be protected despite the technique. Additionally, not all tears are the same and may not be amenable to arthroscopic techniques.

For further questions feel free to contact our office at 616-464-2860.

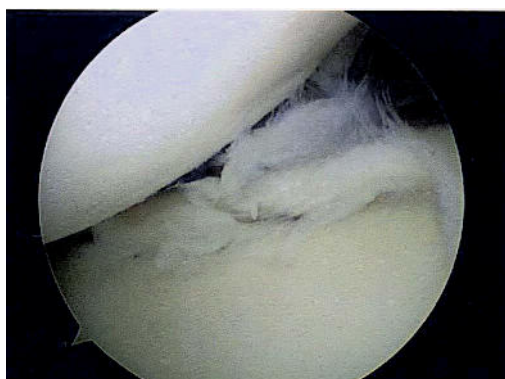
Case 1

History: 32 year old male with history of fall six months ago, who complains of chronic pain and catching.

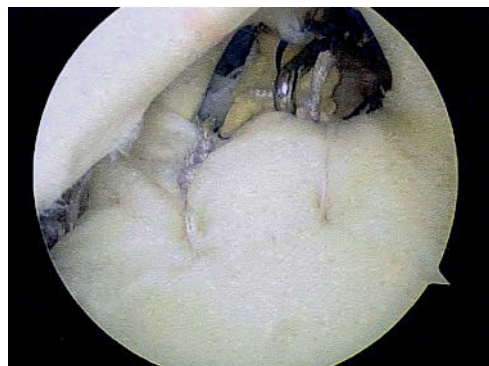
Case Study



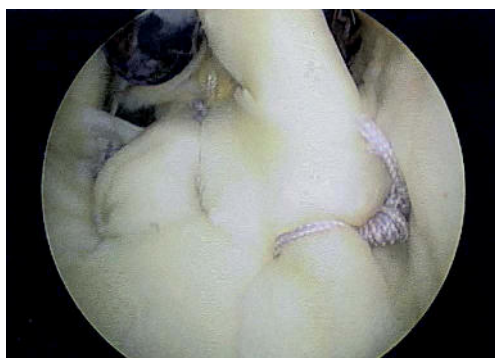
Lateral decubitus position.



Anterior superior labrum tear.



Placement of bioabsorbable suture anchors into the glenoid. Suture is tied with standard sliding knots.

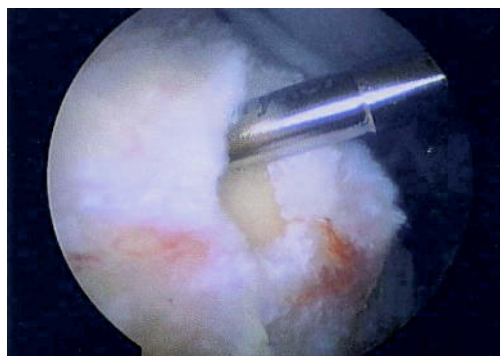


Final result. Labrum is now secured back to the glenoid with three anchors.

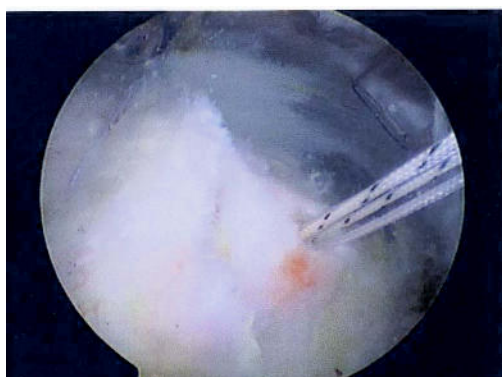Case 2

History: 51 year old male with history of lifting injury, who complains of pain and weakness.

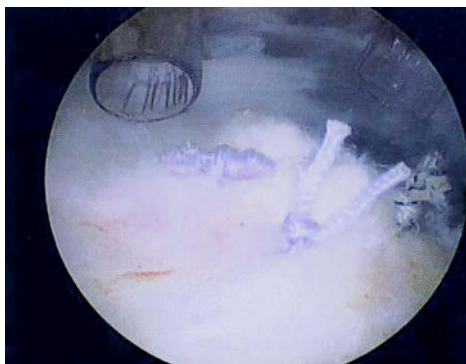
Case Study



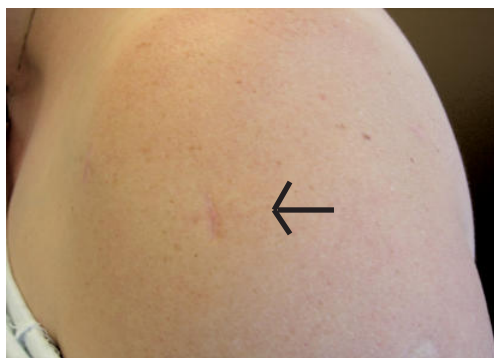
Full thickness elliptical tear of supraspinatus.



Placement of bioabsorbable suture anchors in the humerus.



Repaired tendon secured with arthroscopic sliding knots in double row fixation.

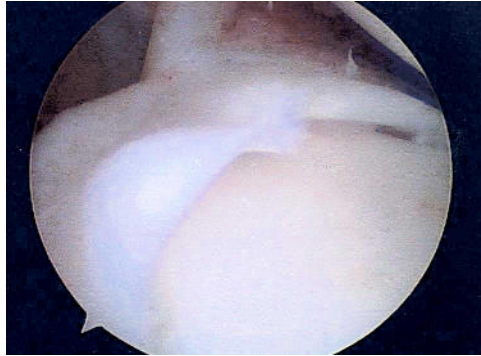

Healed incisions. Total of three incisions, each 1 cm long.

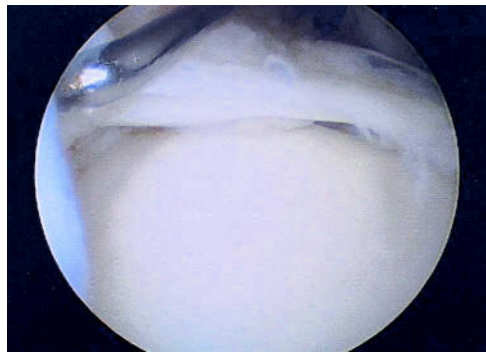Case 3

History: 19 year old female athlete with history of shoulder dislocation and chronic instability.

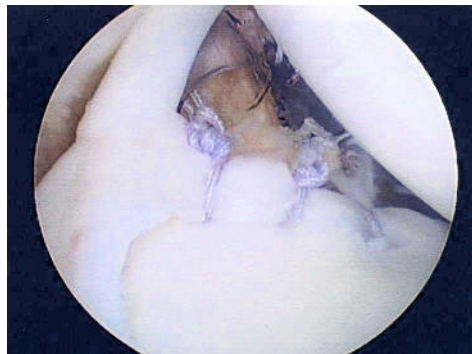Case Study



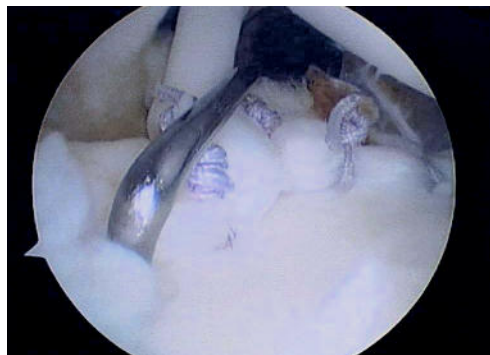
Superior/anterior labrum tear. Patient in lateral decubitus position.



Instability of the labrum shown with probing.



Bioabsorbable suture anchors placed in the glenoid. The labrum and capsule are secured with standard sliding knots.



Final results with the labrum/capsule secured back to the glenoid now stable with probing.